NEUROENDOSCOPIA

HIDROCEFALIAS

LESÕES CISTERNAIS

LESÕES INTRAVENTRICULARES

ASPECTOS HISTÓRICOS

- Hipócrates - Inspeção do reto com luz natural
- Babilônicos – 500AC – espéculos vaginais com luz ambiente
- 1805 – Philippe Bozzini – Inspeção da bexiga e reto com luz de vela refletida
- 1879 – Max Nitze – Primeiro sistema contendo lentes
- 1950 – Utilização de bulbo de tungstênio na ponta dos endoscópios

ASPECTOS HISTÓRICOS

- 1910 – LÉSPINASSE – PRIMEIRA NEUROENDOSCOPIA
- 1922 – DANDY – PLEXECTOMIA CORÓIDE ENDOSCÓPICA
- 1932 – DANDY – PUBLICAÇÃO DE RESULTADOS RUINS
- 1970 – BUCHOLZ E PITTMAN – USO DE Nd:YAG LASER PARA PLEXECTOMIA
- 190 – JONES – SUCESSO EM 50% DAS TERCEIRO VENTRICULOSTOMIAS (TVE)
- SÉRIES MAIS MODERNAS – 60 A 70% DE SUCESSO

DOENÇAS DE TERAPIA ENDOSCÓPICA

- Cistos aracnóides
- Ventrículos septados pós-infecção
- Malformação de Dandy-Waker
- Lesões espinhais
- Hematomas intracranianos espontâneos e pós-traumaticos
- Tumores (especialmente os císticos)
- Tumores de hipófise
- Assistência das microcirurgias

PRINCÍPIOS BÁSICOS DA NEUROENDOSCOPIA

HOPKINS

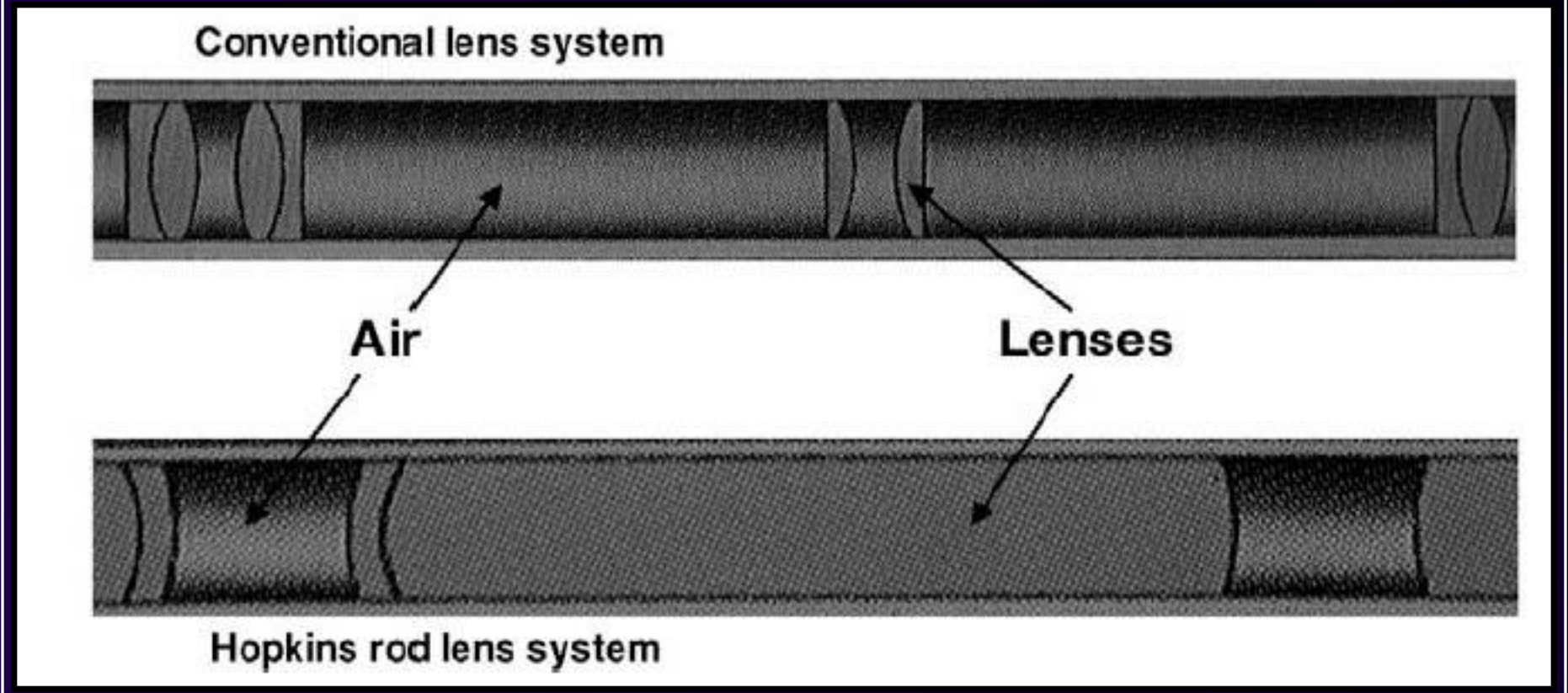

ENDOSCÓPIOS

RÍGIDOS



FLEXÍVEIS

FONTE DE LUZ



MICROCÂMERA/CÂMERA DE CHIP

1.CAMERA DE 1CCD

2.CÂMERA DE 3CCD

Componentes da Neuroendoscopia e Instrumentos

PEEL-AWAY CATHETER

ENDOSCÓPIOS RÍGIDOS

Endoscope	Outer diameter	Channels	Diameter of working channels	Angles of diagnostic scopes	Remark/clinical use
Neuroview 700R (NeuroNavigational)	5.6 mm	1 working 1 irrigation 1 overflow 1 scope	2.0 mm 2.8 mm	0°, 30°, 70°	Glass rod optics, Good image, Quite thick and heavy
Aesculap	6.2 mm	1 working 1 irrigation 1 overflow 1 scope	2.2 mm 2.7 mm	0°, 30°	Glass rod optics, Good image, Quite thick and heavy, Good for stereotaxy
MINOP (Aesculap)	3.2 mm 4.6 mm	1 working/scope 1 working/scope 1 irrigation 1 overflow	2.8 mm 2.8 mm	0°, 30°	Glass rod optics, Good image, Short, maneuverable
	6.0	1 working 1 irrigation 1 overflow 1 scope	2.2 mm 2.8 mm		
Gaab endoscope (Storz/Codman & Shurtleff)	6.5 mm (5.8 mm)	1 working 1 irrigation 1 overflow 1 scope	3.0 mm (4.0 mm)	0°, 30°, 70°, 120°	Glass rod optics, Good image, Quite thick and heavy
Chavantes-Zamorano (Storz/Codman)	8.0 mm	1 working/scope 1 irrigation 1 overflow	3.0 mm (1.9 mm)	0°, 30°, 70°	Glass rod optics, Good image, Quite thick and heavy, Features manometer for ice intracranial measurement, Good for evacuation of hematomas
Auer endoscope (Storz)	6.6 mm	2 working 1 irrigation 1 overflow 1 scope	 3.0 mm	0°	Glass rod optics, Good image, Quite thick and heavy, Adapter for Greenberg retractor
Decq endoscope (Storz)	Oval 3.5 × 5.2 mm	1/2 working 1 irrigation 1 overflow 1 scope	1.7 mm 3.0	30°	Glass rod optics, Good image
	Oval 4.0 × 7.0 mm	1/2 working 1 irrigation 1 overflow 1 scope			Glass rod optics, Good image, Quite thick and heavy

ENDOSCÓPIOS RÍGIDOS

DESVANTAGENS

1. EM GERAL DE DIÂMETRO MAIOR QUE OS FLEXÍVEIS
2. CONTAMINAÇÃO CRUZADA
3. RACHADURA E RASGOS NAS LENTES

ENDOSCÓPIOS FLEXÍVEIS

POUCOS TIPOS

- AESCULAP

1. CODMAN
2. MACHIDA

INSTRUMENTOS DE TRABALHO



INSTRUMENTOS DE TRABALHO

COMPARAÇÃO DE ENDOSCÓPIOS

Comparison of rigid and flexible scopes

	Rigid scopes	Flexible scopes
Advantage's	Better image	Steerability
	Higher resolution	Application in spine
	Wider view	*For some light weight, because camera not attached to scope*
	Better color	
	Better light transmission	
	Light weight of disposable scopes	
Disadvantages	Less maneuverable	Poor image
	Not applicable in spine	Pixel granules
		Narrower view
		Less true color
		Worse light
		Smaller working channel
		Limited selection of scopes and instruments

TREINAMENTO/CURVA DE APRENDIZADO

TRABALHO EM PORTAIS

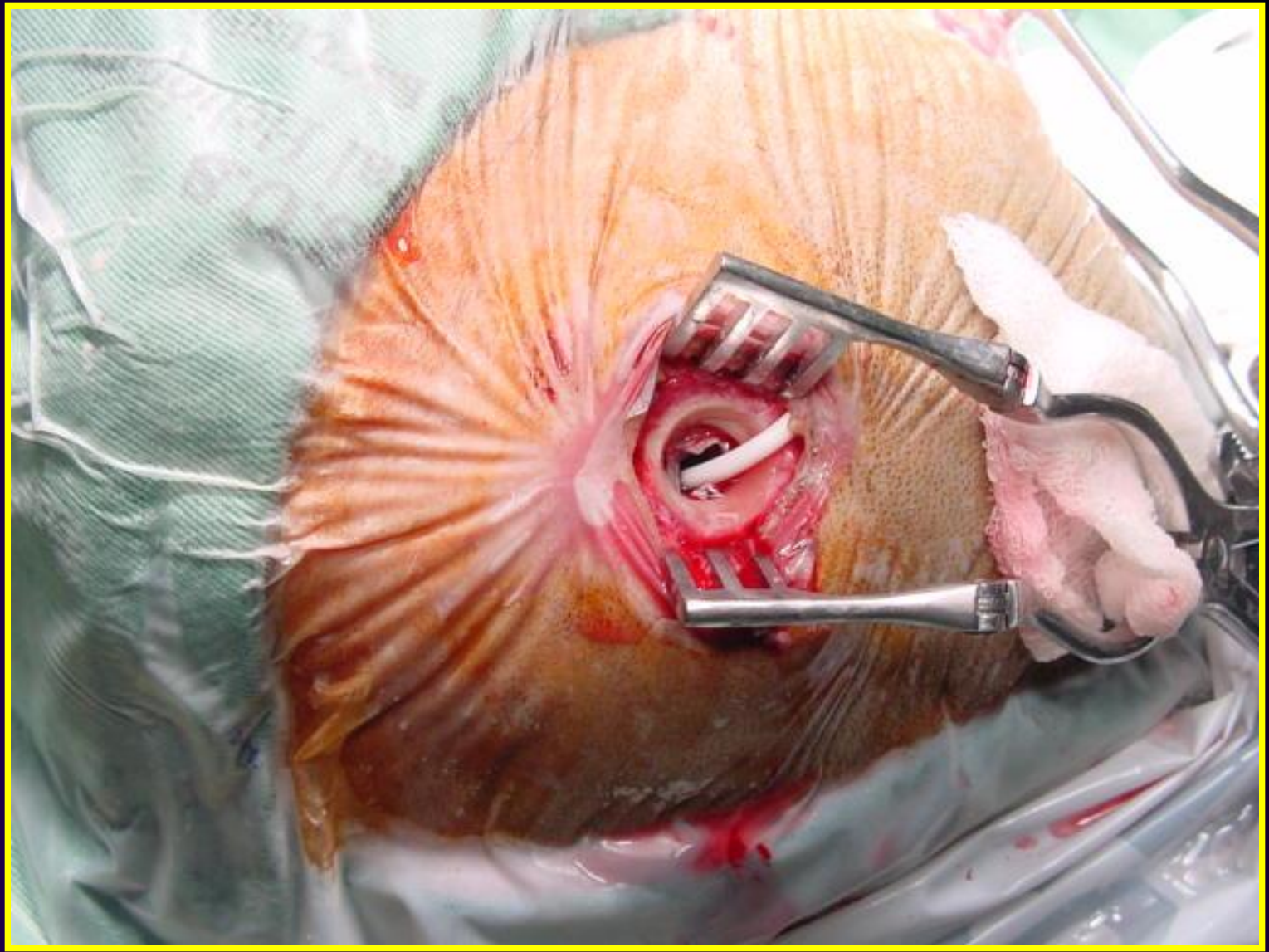

APLICAÇÕES CLÍNICAS

1. Tratamento das lesões intraventriculares
2. Tratamento dos cistos colóides
3. Tratamento das lesões intra-axiais
4. Tratamento da lesões da base do crânio
5. Tratamento dos cistos aracnóides
6. Endoscopias dos seios paranasais
7. Endoscopias neuro-otológicas
8. Endoscopia do sistema nervoso simpático
9. Endoscopia espinhal
10. Tratamento da síndrome do túnel do carpo
11. Hidrocefalias

Tratamento das lesões intraventriculares

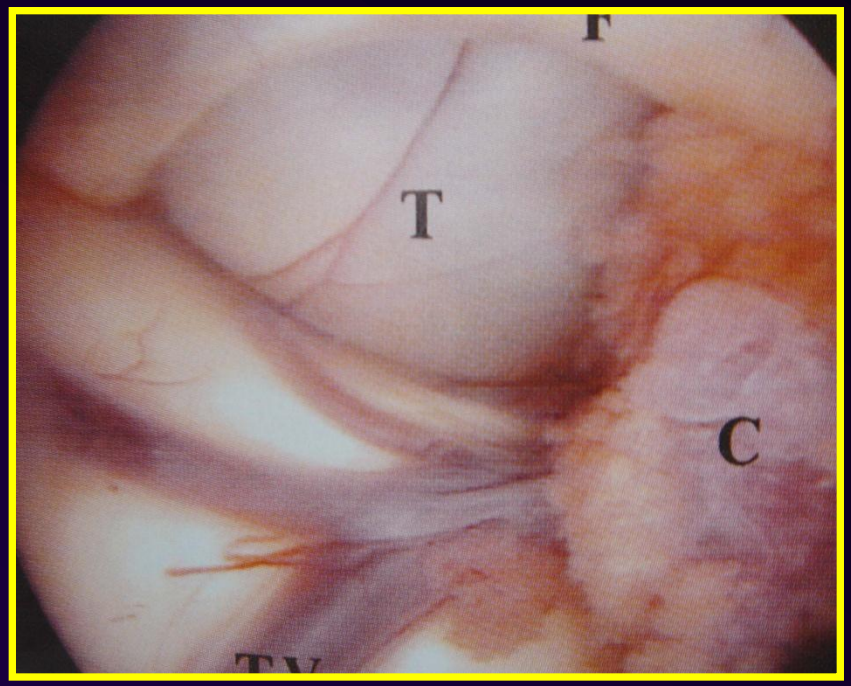

Tratamento das lesões intraventriculares

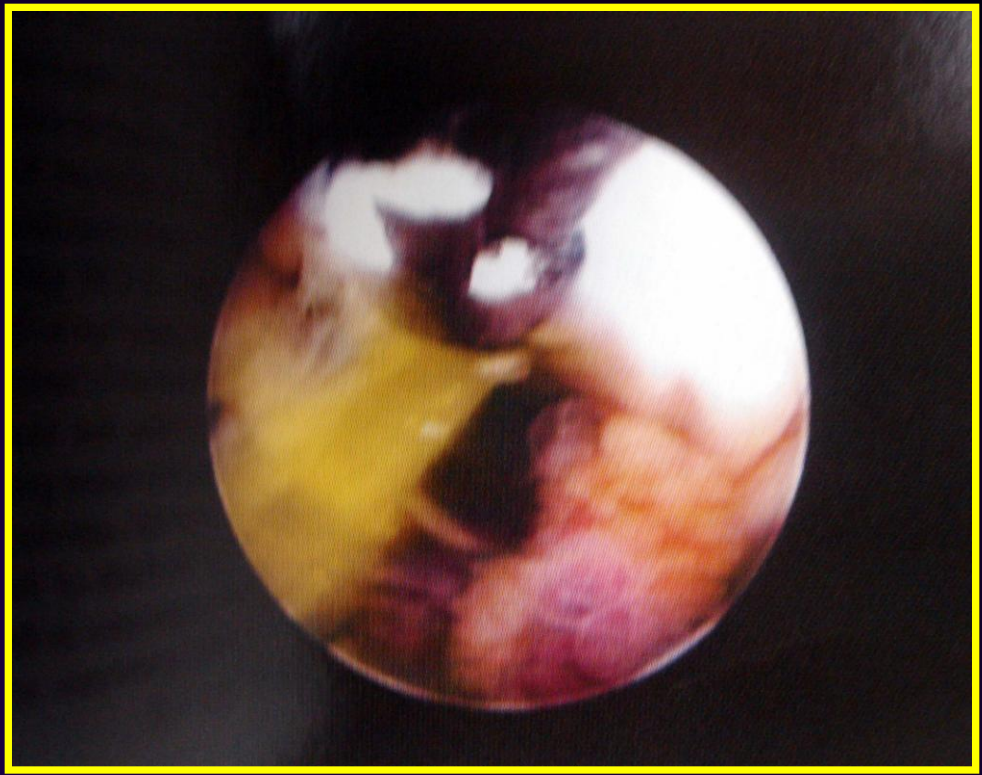

TRATAMENTO DA HIDROCEFALIAS

1. TERCEIROVENTRICULOSTOMIA ENDOSCÓPICA
2. PLEXECTOMIA CORÓIDE
3. AQUEDUTOPLASTIA

AQUEDUTOPLASTIA

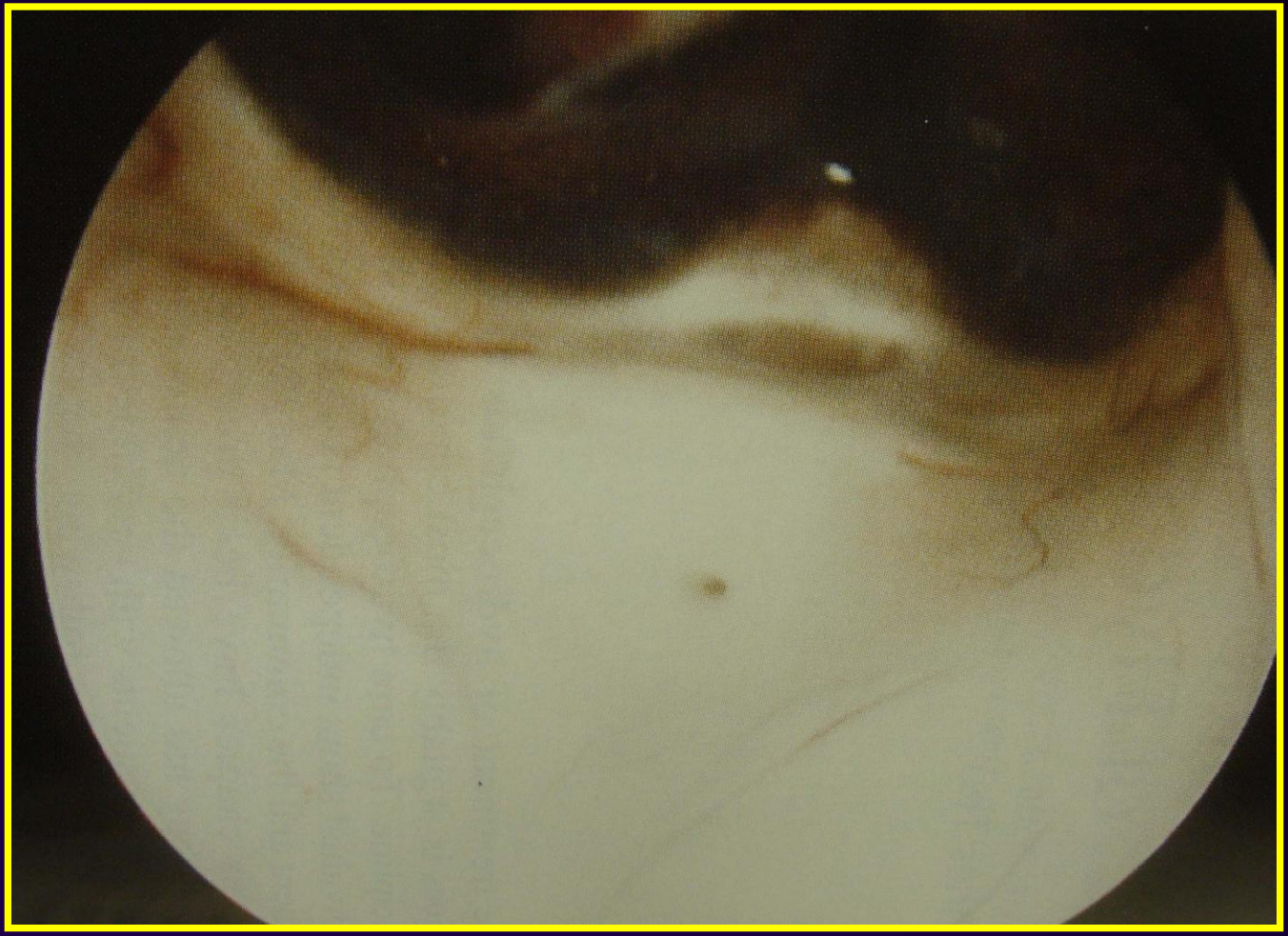

TERCEIROVENTRICULOSTOMIA

1. PROCEDIMENTO SIMPLES
2. PODE SER REPETIDO
2. EVITA USO DE DERIVAÇÕES VENTRICULARES
3. BONS RESULTADOS
3. BAIXO ÍNDICE DE COMPLICAÇÕES
4. BAIXO CUSTO
4. PERÍODO CURTO DE INTERNAÇÃO

TERCEIROVENTRICULOSTOMIA

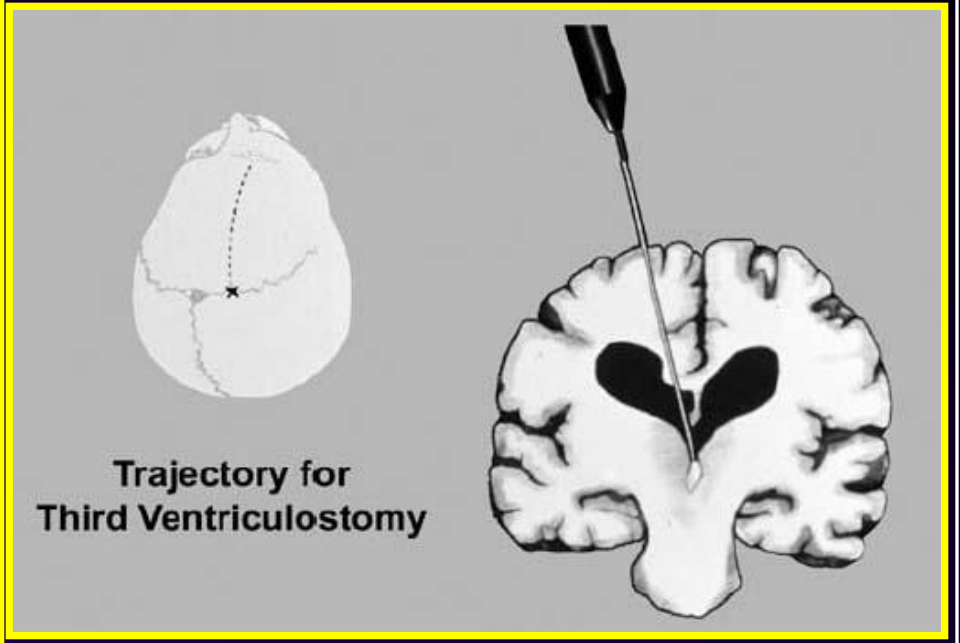

TERCEIROVENTRICULOSTOMIA

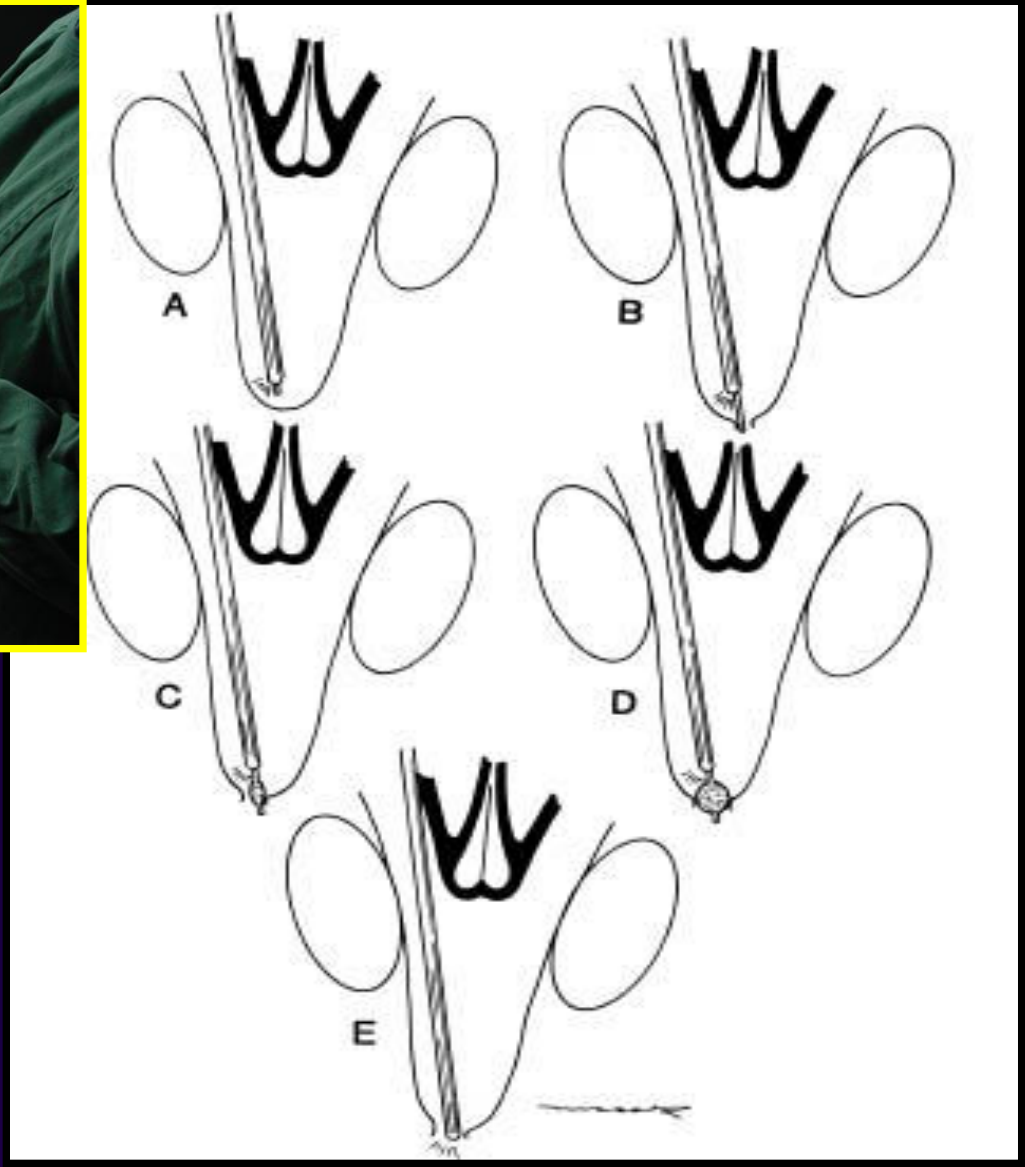

TERCEIROVENTRICULOSTOMIA

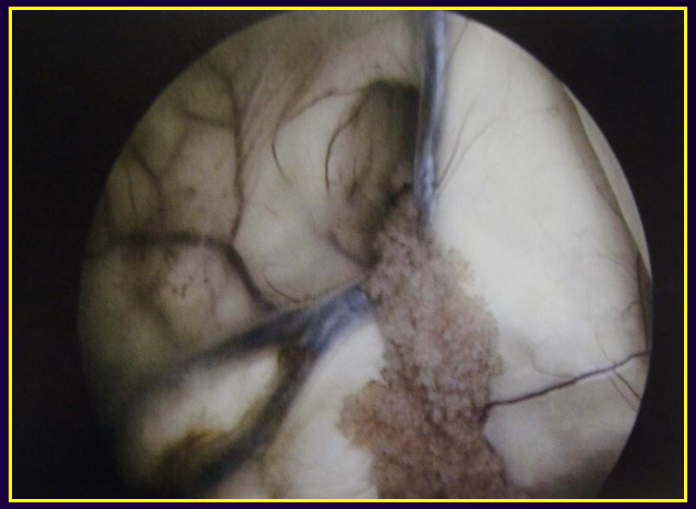

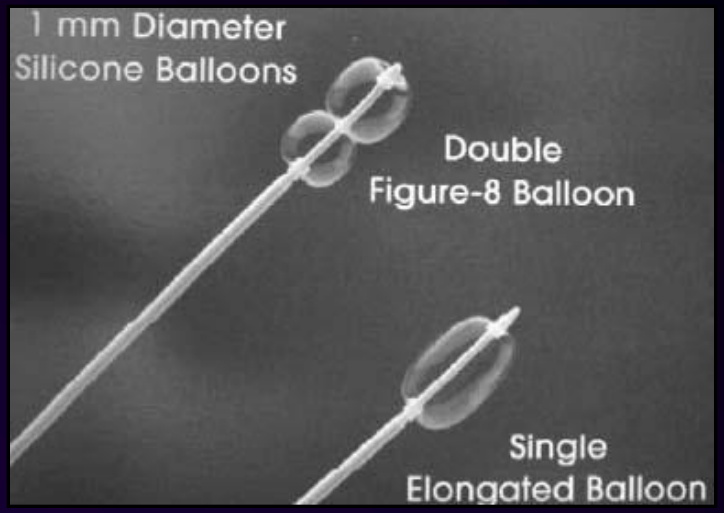

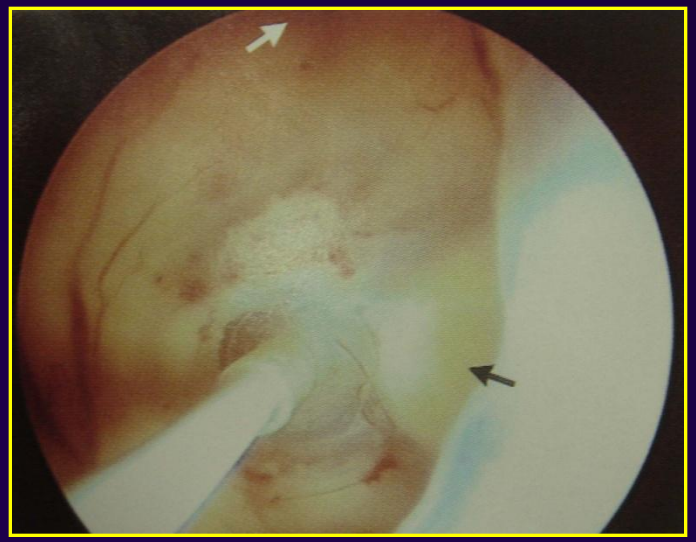

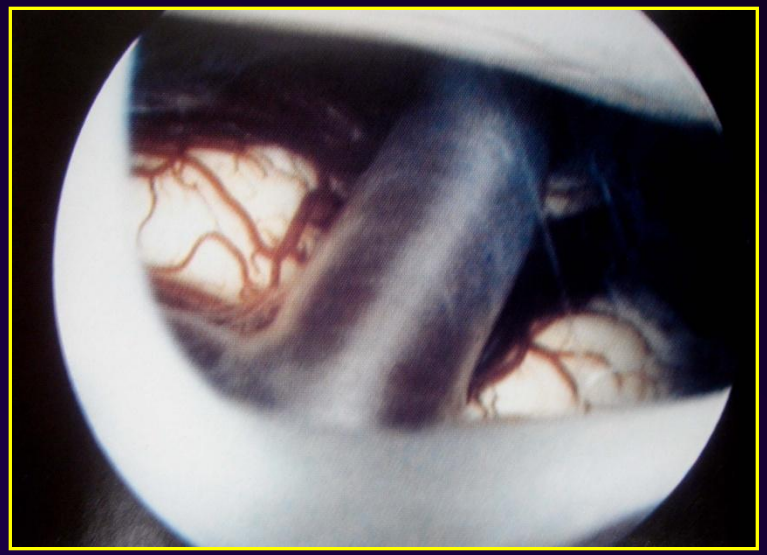

TERCEIROVENTRICULOSTOMIA

PRINCÍPIO

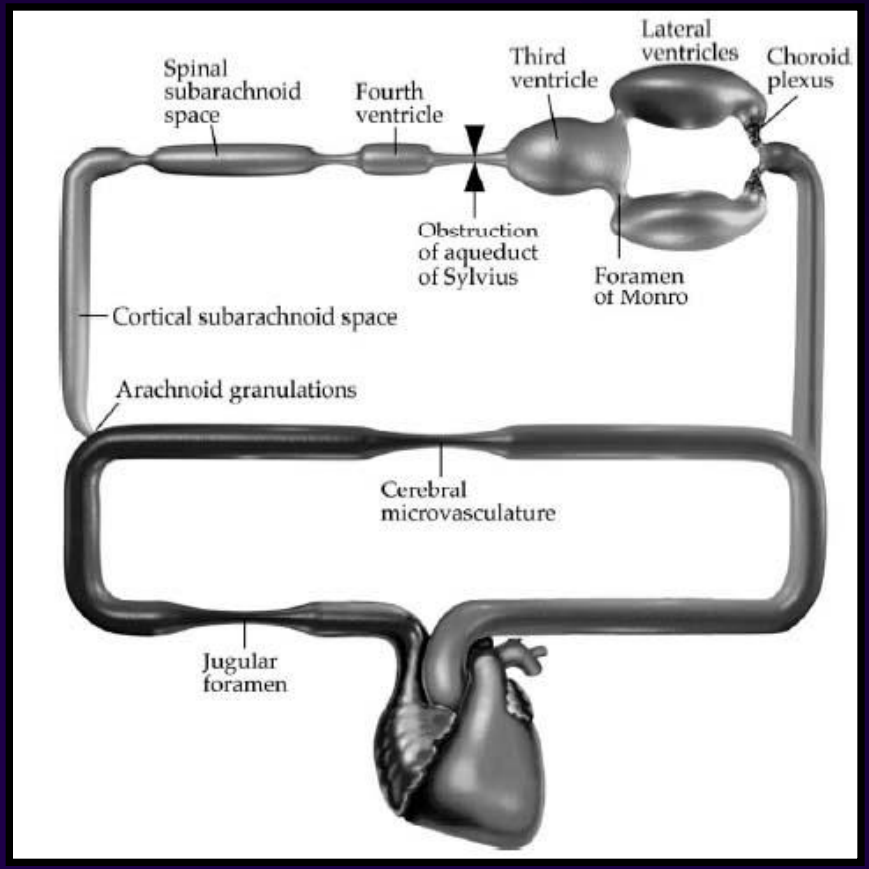

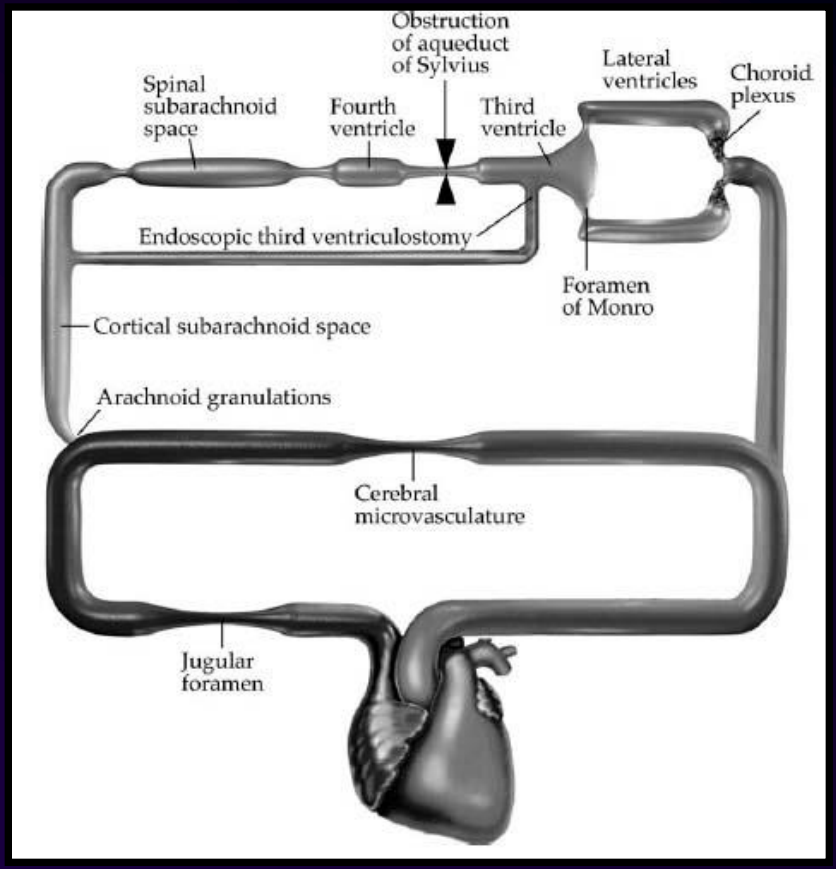

TERCEIROVENTRICULOSTOMIA

SELEÇÃO DE PACIENTES

1. ESTENOSE DE AQUEDUTO (PRIMÁRIA OU SECUNDÁRIA)
2. HIDROCEFALIA TRIVENTRICULAR
2. III VENTRÍCULO OVALADO
3. IDADE ACIMA DE 2 ANOS
3. PRESENÇA DE SHUNT PRÉVIO
4. ASSOALHO FINO E TRANSPARENTE
4. AUSÊNCIA DE HISTÓRIA DE RADIOTERAPIA

TERCEIROVENTRICULOSTOMIA

INDICAÇÕES POSSÍVEIS

1. INFECÇÃO
2. HEMORRAGIA SUBARACNÓIDE
2. MALFORMAÇÃO DE CHIARI
3. HIDROCEFALIA DE PRESSÃO NORMAL

TERCEIROVENTRICULOSTOMIA

CONTRA-INDICAÇÕES ABSOLUTAS

1. HIDROCEFALIA COMUNICANTE
2. VENTRÍCULO PEQUENOS (NÃO RESPONSIVOS)

TERCEIROVENTRICULOSTOMIA

RESULTADOS

Outcome of endoscopic third ventriculostomy by etiology

Author/Year	Age mean (range)	Morbidity	Procedure abort rate	Follow-up mean (range)	Success rate (%) by etiology (n)			
					Tumor/AS	Dysraphic	PHH/PIH	Other (n-etiology)
Jones et al / 1990 [11]	(4 M–17 Y)	8%	16%	N/R	59% (17)	40% (5)		
Jones et al / 1992 [6]	(PNB–78 Y)	7%	9%	27 M (3 M–7 Y)	68% (19)	40% (10)	0% (2)	
Jones et al / 1994 [7]	N/R	5%	6%	N/R	80% (25)	52% (21)		
Sainte-Rose and Chumas / 1996 [8]	5.3 Y	N/R	N/R	1.8 Y	81% (82)			
Teo and Jones/ 1996 [12]	11 Y (1 W–32 Y)	3%	9%	32 M (1 μ–17 Y)		72% (69)		
Gournerova and Frim / 1997 [47]	11.2 Y (2 D–36 Y)	9%	N/R	17 M (7 μ–44 M)	70% (20)		0% (1)	100% (2-IDO)
Baskin et al / 1998 [30]	17.3 Y (1.5–49 Y)	12%	N/R	(21.4 M)				64% (22-SVS)
Brockmeyer et al / 1998 [13]	8.1 Y (1 D–29.5Y)	6%	26%	24.2M (15 μ–69 M)	59% (34)	50% (16)	0% (7)	
Buxton et al / 1998 [16]	3.7 M (0 M–10 M)	15%	0.4%	N/R (6 μ–42 M)	57% (7)	0% (2)	10% (10)	20% (5-IDO)
Buxton et al / 1998 [15]	2 M (0–11 M)* All PNB	21%	11%	(6 μ–42 M)	43% (7)		30% (10)	
Tuli et al / 1998 [37]	8.1 Y (0 M–18 Y)	N/R	N/R	N/R (1 Y–11 Y)	66% (32)			
Gangemi et al / 1999 [10]	31 Y (7 D–81 Y)	12%		28 M (12 μ–54 M)	91% (110)			
Cinalli et al / 1999 [4]	NR (1 M–18 Y)	N/R	6%	2.1 Y (4 D–9 Y)	86% (119)			
Hopf et al / 1999 [9]	36 Y (3 W–77 Y)	6%	2%	26 M (3 μ–71 μ)	83% (82)		63% (8)	
Tisell et al / 2000 [26]	48 Y (17–80 Y)	N/R	N/R	37 M (3 M–5 Y)	50% (18)			

TERCEIROVENTRICULOSTOMIA

COMPLICAÇÕES

- Fístula liquórica
- Pneumoencéfalo

1. Ventriculite
2. Hematoma subdural
2. Lesão das estruturas ventriculares
3. Bradicardia/assistolia
3. Complicações vasculares

OBRIGADO